

MammoExplorer: An Advanced CAD Application for Breast DCE-MRI

Ernesto Coto* Sören Grimm† Stefan Bruckner†
Meister Eduard Gröller† Armin Kanitsar‡ Omaira Rodriguez*

*Computer Graphics Lab, Central University of Venezuela, Venezuela

†Institute of Computer Graphics and Algorithms, Vienna University of Technology, Austria

‡Tiani Medgraph, Austria

Abstract

Currently X-ray mammography is the most widely used method for early detection of breast cancer. However, the use of Dynamic Contrast Enhanced MRI (DCE-MRI) has gained wider attention, since it considerably improves tumor detection and classification by analyzing the flow of contrast agent within the breast tissue.

In this paper we present MammoExplorer, a CAD application that combines advanced interaction, segmentation and visualization techniques to explore Breast DCE-MRI data. Our application uses Brushing and Linking, Two-level Volume Rendering, Importance-driven Volume Rendering, and False Color Maps. In addition, we present Enhancement Scatterplots, a novel graphical representation of DCE-MRI data, novel segmentation approaches, and a new way to explore time-varying CE-MRI data.

1 Introduction

Cancer is a disease that causes cells in the body to divide and reproduce abnormally without control. These cells may join together to form a mass of extra tissue known as a tumor. A tumor is classified as either benign or malignant. A *benign* tumor is not cancerous and does not spread to other sites in the body. In contrast, a *malignant* tumor is cancerous; it can penetrate and destroy healthy body tissues, as well as travel to other parts of the body. Breast cancer refers to a malignant tumor that has been developed from breast cells. Excluding skin cancers, breast cancer is the most common cancer among women, accounting for nearly one of every three

cancers diagnosed in the US [14], and one case of every eight in Europe [1]. The best way to fight breast cancer is early detection.

The most widely used radiological means of early detection of breast cancer is X-ray Mammography, where low doses of radiation produce X-rays, obtaining high-quality 2D images of the breast tissue on a film. Although X-ray Mammography is standard in clinical practice, it has shown lower sensitivity to certain high risk cases [5], dense breasts cases [12], or breast implants [8]. Therefore, other imaging techniques are applied to cancer detection, such as Magnetic Resonance Imaging (MRI), Ultrasound, Tomosynthesis, etc [13]. The use of MRI in breast imaging (termed MR mammography or Breast MRI) has gained considerable attention in recent years, especially for high risk cases [5].

Breast MRI is a non-invasive procedure that uses magnetic fields and radio waves to produce digital images of breast tissue. Each study comprises hundreds of images, cross-sectional in all three directions (side-to-side, top-to-bottom, front-to-back), which are then viewed by a radiologist. Usually, Contrast Enhanced MRI (CE-MRI) is performed, where a contrast agent is used to enhance the tissue structure to assist in determining the location of the disease. In general, MRI collects signals from water protons. The presence of a contrast agent creates magnetic fields approximately one thousand times stronger than those corresponding to water protons. Therefore it appears brighter than regular tissue in MRI images. Breast tumors grow their own blood supply network once they reach a certain size; this is the only way they can continue growing. As the contrast agent is usually absorbed by highly vascularized tissues, possible tumors are highlighted. Both benign and malignant tumors absorb the contrast agent.

In order to classify the possible tumors, the flow

*{ecoto|omaira}@opalo.ciens.ucv.ve

†{grimm|bruckner|groeller}@cg.tuwien.ac.at

‡armin@tiani.com

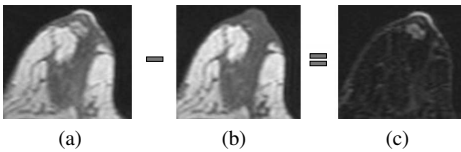


Figure 1: Subtraction of MRI scans to highlight enhanced areas. (a) postcontrast image (b) precontrast image (c) subtraction a-b.

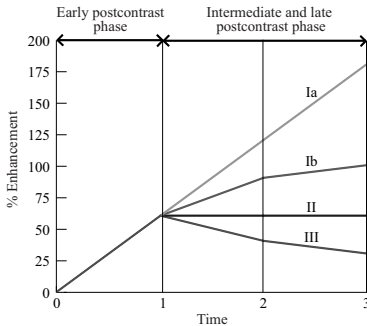


Figure 2: Schematic drawing of the time-signal curve types.

of the contrast agent is analyzed. Usually, several MRI scans are acquired over a period of time, once the contrast agent is introduced into the person's body. This process is called Dynamic CE-MRI (DCE-MRI). These postcontrast scans are subtracted from a precontrast scan in order to highlight suspicious regions, as shown in Figure 1.

A contrast agent flow chart can be generated, taking all the subtracted scans. For each specific location within the breast a curve is generated showing the enhancement of contrast agent over time with respect to the postcontrast scans. Such a curve is referred to as time-signal intensity curve [6] (also called time-signal curve). For breast lesions, different major types of time-signal curves can be identified, as shown in Figure 2. Time 0 corresponds to the precontrast scan.

These curves are classified according to the flow of the contrast agent over time. Curves showing low or no increase in the early postcontrast phase correspond to healthy tissue, and therefore they are not studied. Three major types are distinguished: continuous and reduced increase, constant intensity, and decrease in the intermediate and late postcon-

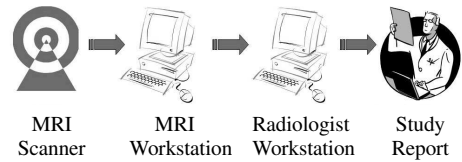


Figure 3: Breast MRI study analysis workflow.

trast phase. Type Ia corresponds to a continuous increase. Type Ib corresponds to a reduced increase due to saturation effects. Type I curves are referred to as *persist*. Type II shows no change in intensity. It is referred to as *plateau*. Type III corresponds to a decrease in the intermediate and late postcontrast phase. It is referred to as *washout*.

According to a study of over two hundred sixty-six breast lesions performed by Kuhl et al. [6], Type I curves are rated to be indicators of benign lesions, Type II are rated as suggestive of malignancy, and Type III are rated as indicative of a malignant lesion.

It is also possible to classify tumors according to their shape [11]. Tumors with sharp margins and an abrupt interface with the surrounding tissue are benign in most of the cases. Classic breast cancer has an irregular boundary as they invade the surrounding tissue producing an ill-defined interface.

Currently, hospitals performing Breast MRI exams have a fixed workflow to analyze patient studies. Often, once the data is acquired, a technologist manually creates subtraction images at the MRI workstation, and then sends them to the radiologists workstation for examination, see Figure 3. Then the radiologist manually goes through all the slices and searches for suspicious regions. This is a very time consuming task, as these regions can be very small. It is quite likely to miss suspicious regions due to the human factor. Once a suspicious region is detected the radiologist has to analyze this region. This is done manually by specifying a region of interest (ROI) within this region. For this ROI a corresponding time-signal curve is computed and then the region is classified. This process has to be repeated for every suspicious region, and therefore the examination usually takes around 30-40 minutes. This kind of examination requires constant attention of the radiologist over a very long period of time. Furthermore, a radiologist performs several studies during a day which can lead to fatigue and

therefore to inattention during the examination.

We propose to optimize this workflow by exploring Breast DCE-MRI data using a sophisticated combination of interaction, segmentation and advanced visualization techniques. In this paper, we present MammoExplorer, the prototype of a novel application to explore Breast DCE-MRI data combining brushing [7] with multiple linked views [2], advanced volume rendering techniques [9, 16, 4], and a new graphic representation of DCE-MRI data, called enhancement scatterplot.

2 Related Work

Subramanian et al. [15] presented a system to identify, process, visualize and quantify lesions from Breast DCE-MRI volumes, based on time-signal curves. The system takes as input five consecutive CE-MRI volumes. The user has to specify a time-signal curve that roughly reflects the type he is looking for. Alternately, a user may pick a few voxels central to a lesion, and examine their time-signal curves. This requires the radiologist to find the suspicious regions manually. According to the similarity to the specified curve a confidence degree of malignancy is assigned to each voxel and displayed in different intensities of red. By using this approach the user is limited to detect only lesions with time-signal curve behavior which is approximately similar to the specified mean curve. Thus, if there is a different type of tumor, with a different time-signal curve, the radiologist could miss this type. Another approach by Carotenuto et al. [3] employs time-signal curves of DCE-MRI volumes to automatically display a False Color Map (FCM). Each type of curve is mapped to a different color. All regions corresponding to the different types of curves are simultaneously displayed using different colors. However, it is a discrete mapping as opposed to a smooth transition between the different kind of curves. Therefore it is not possible to distinguish uncertain regions from certain regions, which can lead to a wrong interpretation.

We propose a novel approach which is capable of overcoming these limitations, by allowing a more intuitive exploration, several types of presentations of the data in 2D and 3D, and advanced segmentation features. All components are integrated with advanced linking and brushing of the data in a highly interactive way.

3 Overview of MammoExplorer

MammoExplorer is integrated into a commercially available medical workstation, shown in Figure 11 (color plate). It requires as input a DCE-MRI sequence containing at least two timesteps. The first volume in the sequence is a precontrast timestep, and the others are postcontrast timesteps. Once MammoExplorer is started it automatically computes, for every postcontrast timestep in the input sequence, its subtraction from the precontrast timestep. Afterwards MammoExplorer displays a control panel, an enhancement scatterplot for each subtracted volume, one 3D view, one time-signal curve view, and three cross-sectional views (sagittal, coronal and axial).

The enhancement scatterplots serve as an interface for a sophisticated segmentation algorithm. They allow the radiologist to brush the Breast DCE-MRI data in an intuitive way. Every interesting region can be explored with the traditional slice-through approach using the cross-sectional views. Furthermore, we have incorporated a 3D view that is able to display advanced volume renderings of the data and the ROIs. A time-signal curve view is also available for radiologists that are used to this method. All views are linked to each other for effective correlation of all the data.

In the following sections we describe how to accomplish segmentation, visualization and exploration of DCE-MRI data, and how all the views of MammoExplorer are linked to each other.

4 Segmentation of DCE-MRI Data

A radiologist is trained to distinguish suspicious breast tissue from the normal tissue. In computer graphics this is accomplished by segmenting the data. MammoExplorer is capable of segmenting the DCE-MRI data using enhancement scatterplots and cropping the DCE-MRI data.

4.1 Enhancement scatterplots

An enhancement scatterplot for Breast DCE-MRI data shows the positive percentage of enhancement of a subtracted volume with respect to the precontrast intensity values. The precontrast timestep is referred to as t_0 . All postcontrast scans are enumerated according to their acquisition time (t_1, \dots, t_n) .

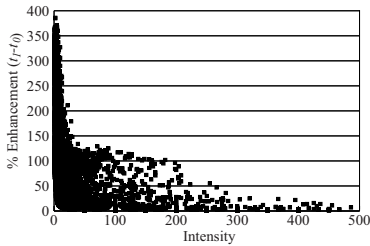


Figure 4: Enhancement scatterplot for subtracted volume t_1-t_0 .

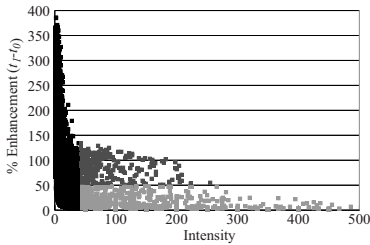


Figure 5: Enhancement scatterplot for subtracted volume t_1-t_0 , divided into three categories.

The relative enhancement of t_0 intensities with respect to timestep t_i intensities is calculated according to Equation 1 as in [6]. Pixels in t_0 with intensity zero are not taken into account, since they are not part of the breast area. In Figure 4 an example enhancement scatterplot is shown, where a (x,y) point indicates that a voxel with intensity x in t_0 had an enhancement of $y\%$ by the time t_1 was acquired.

$$\%Enhancement(t_i - t_0) = \frac{(t_i - t_0)x100}{t_0} \quad (1)$$

An enhancement scatterplot is designed in such a way, that it allows brushing by means of a selection box, where all points inside the box are accounted for selection. Up to three independent selection boxes are supported, distinguished by different colors, as shown in the enhancement scatterplots of MammoExplorer in Figures 11a to 11d (color plate). A selection box allows the user to perform a *two-level thresholding*, as it specifies a range for both axes of the scatterplot. This kind of brushing allows to precategorize the data into three major types, as shown in Figure 5.

Black points correspond to voxels with a low intensity value in the precontrast phase. These voxels are most likely air or noise. Light gray points correspond to voxels with small changes in intensity, due to noise, moving artifacts, or low absorption of contrast agent. Dark gray points correspond to voxels with high enhancements, mostly attributed to a high absorption of contrast agent. Radiologists are interested in the dark gray category, but the criterions to set the boundaries between these three categories vary from one study to another, and therefore the placement of the selection boxes has to be interactive. A possible criterion to place the selection boxes on the scatterplots is explained in Section 6.

One enhancement scatterplot displays information about one subtracted volume. Displaying multiple enhancement scatterplots, one for each subtracted volume, allows to display *temporal information*. Thus, the flow of the contrast agent from one timestep to the next can be studied. In order to support brushing over time we propagate the selection made in one enhancement scatterplot to the other enhancement scatterplot. Brushed points are highlighted in all views, as shown in Figures 11a to 11d (color plate). In the case where several enhancement scatterplots have a selection box a logical *and* is performed on the selections. The radiologist selects only those points common to all selections, and therefore refines the selection taking into account information in the other timesteps. This way the user can brush a set of voxels from the dataset, and study the flow of the contrast agent through all acquired timesteps.

Once the user has made a selection using the enhancement scatterplots, all the other views are immediately updated, as explained in Section 5.

4.2 Cropping the DCE-MRI volume

In general, every enhancement scatterplot shows the whole information of one subtracted volume. Furthermore, we allow "cropping" the volume and focus the attention to a specific part of the breast. After cropping, the size of the data is reduced and the signal-intensity scatterplots display less data, allowing a more detailed selection. In Figures 11g and 12g (color plate), the user has cropped the volume drawing a rectangle in the axial view. The DCE-MRI volume is then cropped according to the rectangle, triggering an update of all linked views.

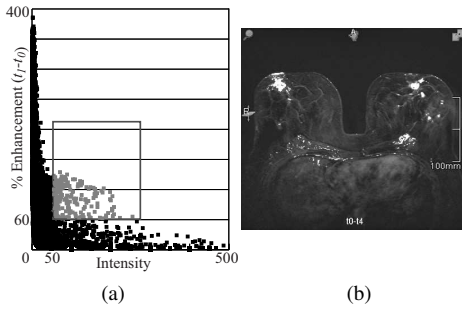


Figure 6: Linking a single selection in a t_1-t_0 enhancement scatterplot. (a) brushed selection (b) axial view with FCM.

5 Visualization of DCE-MRI Data

The radiologist is also interested in the spatial location, shape and extent of the possible lesions. Therefore we visualize the brushed regions in the context of the patient's breast. MammoExplorer provides the radiologist with 2D and 3D views. It displays three cross-sectional 2D views of the data with False Color Maps (FCMs) highlighting the brushed areas. Furthermore advanced volume rendering techniques are used to provide the radiologist with a 3D view of the lesions maintaining the breast context for a better spatial understanding.

5.1 False Color Maps

It is straightforward to obtain the spatial position of the brushed pixels. The subtracted volumes are quickly browsed looking for pixels with the characteristics specified by each selection box. Once the spatial locations are computed, it is possible to create a False Color Map for each brushed area, that is superimposed onto the 2D cross-sectional views.

Figure 6 shows the brushing of all regions with an enhancement over 60% right after contrast injection, linked with an axial view of the subtracted volume t_1-t_0 with a superimposed FCM. Since multiple FCMs may overlap, an interaction method to show and hide any brushed region is provided in the panel. The radiologist can also slice-through the 2D cross-sectional images, in order to visualize the FCMs in the whole MRI image stack.

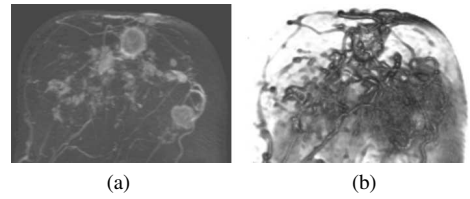


Figure 7: Volume Rendering of the breast (a) MIP (b) CRC.

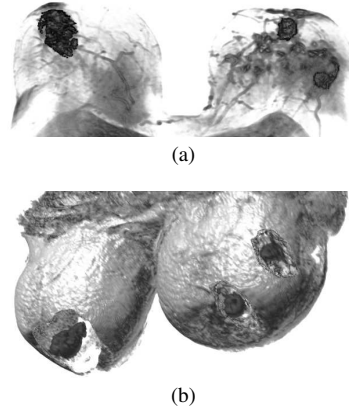


Figure 8: Focus+context volume visualization showing three brushed tumors in a patient's breast (a) Two-level Volume Rendering (b) Importance-driven Volume Rendering.

5.2 Volume Rendering

Since MRI is a 3D imaging technique, it is possible to display a volume rendering of the subtracted volume to visualize the shape of the lesion in an efficient and timely manner. Maximum Intensity Projection (MIP) [10] can be used, or Composite Ray Casting (CRC) as shown in Figure 7.

We propose the creation of a bitmask volume for every brushed ROI in the enhancement scatterplots, so a Two-level Volume Rendering [9, 4] can be applied. This strategy allows to selectively choose the most suitable technique for depicting each ROI within the data, while keeping the context of the breast visible at a reasonable level. Figure 8a shows three brushed tumors and the breasts rendered using CRC, with different transfer functions for each component. Notice that the lesions are simultaneously visualized while the breast context is rendered semi-transparently, providing a focus+context visu-

alization. A wide range of different rendering methods can be applied simultaneously once the bit-masks are created.

Importance-driven Volume Rendering [16] can also be applied, giving more importance to the radiologist's selection and less importance to the rest of the tissue. This also produces focus+context volume visualization of the radiologist's selection, as shown in Figure 8b. Hereby a better 3D understanding is given when interactively changing the view direction. *Automatic importance assignment* is performed, by brushing areas in the breast showing more than a specific relative enhancement in the early postcontrast phase.

5.3 Exploration of DCE-MRI data

MammoExplorer provides three ways to analyze the temporal DCE-MRI data.

One way is a time-signal curve chart, as shown in Figure 11f (color plate). A mean time-signal curve is computed for every brushed region. All mean curves are displayed simultaneously in the time-signal curve view, so the radiologist can compare the enhancement patterns of every ROI.

Another way is to view all subtracted volumes either in 2D or 3D using different rendering approaches, in order to have a visual feedback on the enhancement of the suspicious areas. Since every enhancement scatterplot corresponds to one specific subtracted volume, the user can easily specify which volume to display by clicking in the corresponding enhancement scatterplot.

As a third way, we propose a novel exploration mode connecting all the different components of our approach, see Figure 12 (color plate). MammoExplorer allows the radiologist to pick a voxel in an arbitrary slice on any of the cross-sectional views. Then, information about the picked voxel is shown in all the views. On each enhancement scatterplot, the intensity and percentage of enhancement of the picked voxel is displayed, therefore indicating the flow of contrast agent in the picked voxel. In the 3D view the location of the picked voxel is displayed, providing the radiologist with the 3D spatial location of the picked voxel within the breast tissue. In every cross-sectional view, including the one where the user activated the exploration mode, the position of the picked voxel is displayed. The time-signal curves of eight neighboring pixels around the picked pixel are also shown.

In another view, the time-signal curve of the picked voxel is displayed, along with the mean time-signal curves of the brushed regions.

6 Suggested Workflow

Comprehensive interpretation of Breast DCE-MRI studies requires answering the following essential questions:

- Is there an enhancement showing a lesion?
- Where is the lesion located?
- What is the lesion's size?
- Has the tumor traveled to other parts of the breasts?
- Is the tumor benign or malignant?

In order to answer these questions using MammoExplorer, we suggest a new workflow, that considerably reduces the time spent in the workflow shown in Figure 3. In order to explain the steps in our workflow, we take as an example a sequence of five timesteps, of a 42 year old woman with suspicious lesions in the left breast. Once the radiologist loads the DCE-MRI data, MammoExplorer displays the nine views shown in Figures 11 and 12 (both color plate).

The first step of a radiologist is to identify if there is an enhanced lesion or not. In the study of Kuhl et al. [6], a relative signal intensity increase of more than 60% on the first postcontrast image is considered indicative of breast cancer. The user just has to press the button "Suggest Selection" in the panel and MammoExplorer automatically draws a default selection box that blends out the air area and highlights the suspicious lesions according to the criterion of Kuhl et al. [6]. Besides this criterion, the radiologist can quickly brush any desired range of enhancements drawing a selection box in the enhancement scatterplot for the subtracted volume $t_1 - t_0$. The radiologist can also use the exploration mode, to get assistance in the placement of the selection box, quickly visualizing the corresponding position of any specific voxel in the scatterplots.

Whether the radiologist draws a selection box or uses the "Suggest Selection" button, suspicious regions are instantly segmented and highlighted in all views. For each of these suspicious lesions, the radiologist has to perform a more thorough analysis. In the following step the radiologist uses MammoExplorer to find the location, size and type of the tumor.

With MammoExplorer, the location of a possible lesion is visualized directly after the radiologist has brushed a region using the enhancement scatterplots, since these are automatically linked to the 2D and 3D views. The radiologist can visualize right away the location and extent of the tumor in every slice using the cross-sectional views, shown at the bottom of Figures 11 and 12 (both color plate). At the same time, a focus+context volume rendering of the tumor and the breast is shown in the 3D view, always highlighting the tumor, so the radiologist can visualize the 3D location of the tumor inside the breast.

The size of the tumor is also automatically computed and displayed in the 3D view. Since for every ROI a bitmask volume is created, the estimated volume of a lesion is calculated by multiplying the number of active voxels in the bitmask by the size of a voxel in the data. This computation is fast and is shown promptly after the user has identified the suspicious lesions. In addition, the cross-sectional views are used to display the longest diameter of a lesion within a specific slice, which can also be useful for surgery planning.

At this point of the workflow, just a few minutes after loading the DCE-MRI data, the radiologist already has identified the suspicious regions and has information about its size, location and shape. The next important step is to classify the lesion as benign or malignant. This is usually achieved by studying the changes in the enhancement through time and analyzing the shape of the tumor. With MammoExplorer the user immediately visualizes the shape of the tumor using the 3D view, and visualizes its mean time-signal curve, as shown in Figures 11e and 11f (color plate).

Additionally, the radiologist can also perform a refined study of the enhancement changes using the enhancement scatterplot. He just has to add selection boxes in more than one scatterplot. Figures 9 and 10 show possible selections for benign and malignant tumors.

A selection like the one shown in Figure 9, restricts the selection to voxels with a steady increase in the first two postcontrast timesteps, and also with an increase over 60% in the early postcontrast phase. This indicates the lesion is benign. Selected points are shown in gray.

A selection like the one shown in Figure 10, restricts the selection to voxels with an increase of

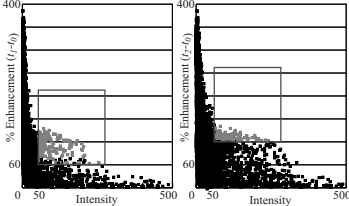


Figure 9: Restricted selection adding linked selection boxes for subtracted volumes t_1-t_0 and t_2-t_0 , searching for a benign tumor.

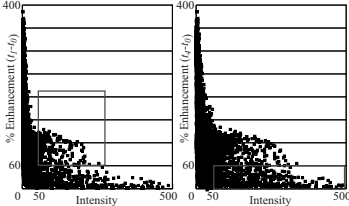


Figure 10: Restricted selection adding linked selection boxes for subtracted volumes t_1-t_0 and t_4-t_0 , searching for a malignant tumor.

more than 60% in the early postcontrast phase, but with an increase below 60% in the late postcontrast phase. This would indicate that the lesion is malignant, but in this study the selection is empty since no point in our example matches both constraints.

In addition, the mean time-signal curve of the suspicious lesion is shown in the time-signal curve view, for radiologists accustomed to this type of display. All this information is shown automatically and immediately after the user has identified the suspicious lesions. Using the time-signal curve view the radiologist can also compare the different mean curves for every brushed ROI. The panel also shows, for every ROI, the percentage of voxels in the ROI with a persist, washout and plateau enhancement pattern.

If the tumor is found to be malignant, then the next step of the radiologist is to ascertain if the tumor has spread to other parts of the breast. The enhancement scatterplots show information of the entire volume. If the tumor has travelled to other tissues around it, a radiologist's selection highlights all of those regions that are interesting, even if they are not connected.

7 Conclusions and Future work

MammoExplorer is an elaborated combination of interaction, segmentation and advanced visualization techniques. This paper demonstrates that it is possible to explore Breast DCE-MRI data combining brushing and linking, advanced segmentation approaches and state-of-the-art volume rendering techniques. We proposed and investigated the usefulness of the enhancement scatterplots as a new graphic representation of DCE-MRI data, and we also presented a novel approach to explore time-varying CE-MRI data. We believe that our application allows the radiologist to perform a more in-depth exploration of the breast and considerably reduces the usual workflow time. We think this will lead to a more accurate diagnosis. The next step is to use MammoExplorer to conduct a medical case study with a large number of women.

8 Acknowledgements

The work presented in this publication has been funded by the ADAPT project (FFF-804544). ADAPT is supported by *Tiani Medgraph*, Vienna (<http://www.tiani.com>), and the *Forschungsförderungsfonds für die gewerbliche Wirtschaft*, Austria. See <http://www.cg.tuwien.ac.at/research/vis/adapt> for further information on this project.

The DCE-MRI datasets used are courtesy of the MR-Institut, Univ.-Klinik für Radiodiagnostik Innsbruck, Austria and the KH Lainz MRT Wien, Austria.

References

- [1] P. Boyle and J. Ferlay. Cancer incidence and mortality in Europe, 2004. *Annals of Oncology* 2005, 16(3):481–488, 2005.
- [2] A. Buja, J. McDonald, J. Michalak, and W. Stuetzle. Interactive data visualization using focusing and linking. In *VIS '91: Proceedings of the 2nd conference on Visualization '91*, pages 156–163, 1991.
- [3] L. Carotenuto, M. Ercolani, R. Passariello, C. Catalano, F. Pediconi, and F. Venditti. Software tool for computer aided diagnosis of breast cancer in contrast enhanced MR sequences. In *EuroPACS-MIR 2004 in the Enlarged Europe*, pages 361–364, 2004.
- [4] M. Hadwiger, C. Berger, and H. Hauser. High-quality two-level volume rendering of segmented data sets on consumer graphics hardware. In *Proceedings of IEEE Visualization 2003*, pages 301–308, 2003.
- [5] M. Kriege, C. Brekelmans, C. Boetes, P. Besnard, H. Zonderland, I. Obdeijn, R. Manoliu, T. Kok, H. Peterse, M. Tilanus-Linthorst, S. Muller, S. Meijer, J. Oosterwijk, L. Beex, R. Tollenaar, H. de Koning, E. Rutgers, and J. Klijn. Efficacy of MRI and mammography for breast-cancer screening in women with a familial or genetic predisposition. *New England Journal of Medicine*, 351(5):427–437, 2004.
- [6] C. Kuhl, P. Mielcareck, S. Klaschik, C. Leutner, E. Wardelmann, J. Gieseke, and H. Schild. Dynamic breast MR imaging: Are signal intensity time data useful for differential diagnosis of enhancing lesions? *Radiology*, 211(1):101–110, 1999.
- [7] J. McDonald, W. Stuetzle, and A. Buja. Painting multiple views of complex objects. In *OOPSLA/ECOOP '90: Proceedings of the European conference on object-oriented programming on Object-oriented programming systems, languages, and applications*, pages 245–257, 1990.
- [8] D. Miglioretti, C. Rutter, B. Geller, G. Cutter, W. Barlow, R. Rosenberg, D. Weaver, S. Taplin, R. Ballard-Barbash, P. Carney, B. Yankaskas, and K. Kerlikowske. Effect of breast augmentation on the accuracy of mammography and cancer characteristics. *Journal of the American Medical Association*, 291(4):442–450, 2004.
- [9] L. Mroz, H. Hauser, G. Bischli, and M. Eduard Gröller. Two-level volume rendering. *IEEE Transactions on Visualization and Computer Graphics*, 7(3):242–252, 2001.
- [10] L. Mroz, H. Hauser, and M. Eduard Gröller. Interactive high-quality maximum intensity projection. *Computer Graphics Forum*, 19(3):C341–C350, 2000.
- [11] R. Rangayyan, N. El-Faramawy, J. Desautels, and O. Alim. Measures of acutance and shape for classification of breast tumors. *IEEE Transactions on Medical Imaging*, 16(6):799–810, 1997.
- [12] F. Sardanelli, G. Giuseppetti, P. Panizza, M. Baz-zocchi, A. Fausto, G. Simonetti, V. Lattanzio, and A. Del Maschio. Sensitivity of MRI versus mammography for detecting foci of multifocal, multicentric breast cancer in fatty and dense breasts using the whole-breast pathologic examination as a gold standard. *American Journal of Roentgenology*, 183(4):1149–1157, 2004.
- [13] A. Smith, P. Hall, and D. Marcello. Emerging technologies in breast cancer detection. *Radiology Management*, 26(4):16–24, 2004.
- [14] American Cancer Society. Breast cancer facts and figures 2003-2004. ACS Web site, 2004.
- [15] K. Subramanian, J. Brockway, and W. Carruthers. Interactive detection and visualization of breast lesions from dynamic contrast enhanced MRI volumes. *Computerized Medical Imaging and Graphics*, 28(8):435–444, 2004.
- [16] I. Viola, A. Kanitsar, and M. Eduard Gröller. Importance-driven volume rendering. In *Proceedings of IEEE Visualization 2004*, pages 139–145, 2004.

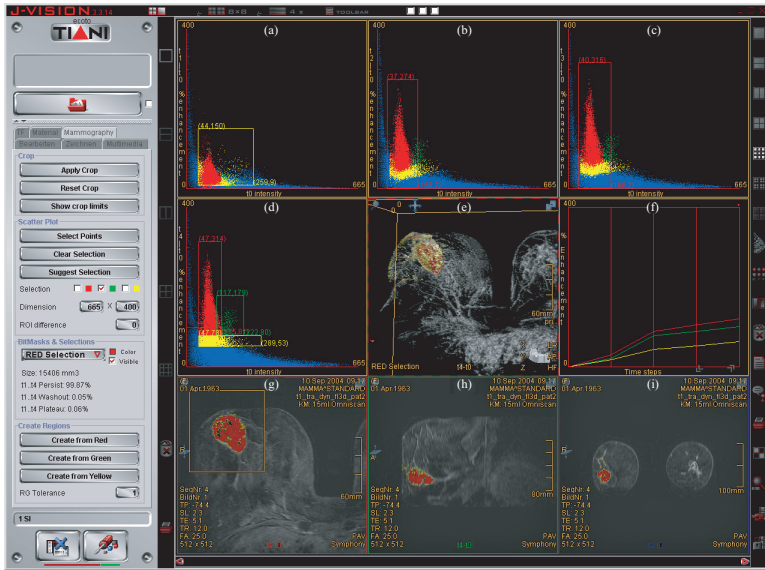


Figure 11: MAMMOEXPLORER working with a DCE-MRI sequence of five scans. (a)-(d) Enhancement scatterplots for subtracted volumes t_1-t_0 , t_2-t_0 , t_3-t_0 and t_4-t_0 . (e) 3D view. (f) time-signal curve view. (g)-(i) axial, sagittal, and coronal views.

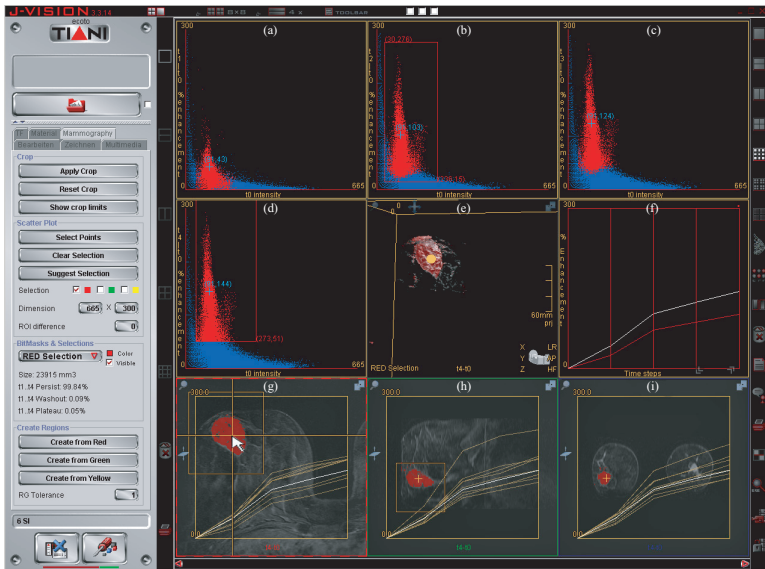


Figure 12: The user picked a voxel using view (g), triggering the update of all views. The position of the voxel is indicated in yellow in views (e), (h) and (i). A small blue cross shows the intensity and the enhancement of the picked voxel in views (a)-(d). In (f) the time-signal curve of the voxel is shown in white, along with other curves. In views (g)-(i) the time-signal curve of eight neighboring voxels are shown.